



PATIENT

Moxie Clemmey

SPECIES

Feline

BREED

DLH

SEX

Female Spayed

AGE

11 years

WEIGHT

13.2lbs

PRESENTING CLINICAL SIGNS

History: Presented for echocardiogram since under anesthesia for a dental cleaning was having multiple runs of VPCs. Cardiac auscultation was normal. Radiographs revealed slight enlargement of cardiac silhouette.

ECHOCARDIOGRAM FINDINGS

2D, m-mode, color flow and Doppler imaging is available.

Left ventricle: The LV diameter is normal with adequate myocardial function. The LV wall thicknesses are largely normal with a focal region of mild septal thickening. There is a diffusely hyperechoic endocardium consistent with fibrosis. The papillary muscles are mildly remodeled and hyperechoic.

Left atrium: The left atrium is normal. No obvious spontaneous contrast or thrombi seen.

Mitral valve: The mitral valve is normal in structure and mobility. No obvious systolic anterior motion is seen. No MR.

Aortic valve/Aorta: The aortic valve is mildly thickened. Normal aortic outflow velocity; laminar flow. Trace aortic insufficiency.

Right ventricle: Normal right ventricular diameter and morphology indicating no overt evidence of pulmonary arterial hypertension.

Right atrium: The right atrium is normal in dimension.

Tricuspid valve: The tricuspid valve appears normal with no tricuspid regurgitation.

Pulmonic valve/Pulmonary artery: The pulmonic valve is normal in morphology and mobility. No pulmonic insufficiency. Normal RVOT velocity; laminar flow.

Pericardium/other: No pericardial or pleural effusion noted. No obvious cardiac masses.

Heart rhythm: ECG reveals a sinus rhythm with an average HR of 170bpm.

INTERPRETED BY

Maggie Machen
Lamy, DVM
DACVIM (Cardiology)

2-Dimensional Measurements

Ao diam (cm)	1.0
LA diam (cm)	1.1
LA:Ao (Swe)	1.1
IVS thickness (cm)	0.65
LVID diastole (cm)	1.5
PW thickness (cm)	0.44
LVID systole (cm)	0.9
FS (%)	40

Doppler Measurements

PV Vmax (m/s)	0.72
AoV Vmax (m/s)	1.0
MR Vmax (m/s)	NA
TR Vmax (m/s)	NA
TR PG (mmHg)	NA

IMAGING

PERFORMED BY

Pamela Harrigan,
RDCS

INTERPRETATION OF THE FINDINGS

Overtly normal cardiac structure and function. The only abnormality identified is a focal septal bulge. This may be an early sign of HCM; however, a normal variant is certainly also a possibility. Regardless, no significant pathology is visualized with a normal left atrial dimension.

HOSPITAL NAME

Wood River Animal
Hospital

REFERRING VET

Dr. Schuelke

INVOICE

22012

DATE

11/12/21

No structural cause for arrhythmias under anesthesia is identified in this study and the screening ECG is unremarkable. Consider a longer tracing, particularly if any arrhythmias are ausculted in the future. An alternative protocol could be utilized and/or consultation with an Anesthesiologist may be useful. Based on what is seen here, there is no contraindication for general anesthesia.

Prognosis is open prior to monitoring for progression.



PATIENT

Moxie Clemmey

SPECIES

Feline

BREED

DLH

SEX

Female Spayed

AGE

11 years

WEIGHT

13.2lbs

INTERPRETED BY

Maggie Machen
 Lamy, DVM
 DACVIM (Cardiology)

IMAGING PERFORMED BY

Pamela Harrigan,
 RDCS

HOSPITAL NAME

Wood River Animal
 Hospital

REFERRING VET

Dr. Schuelke

INVOICE

22012

DATE

11/12/21

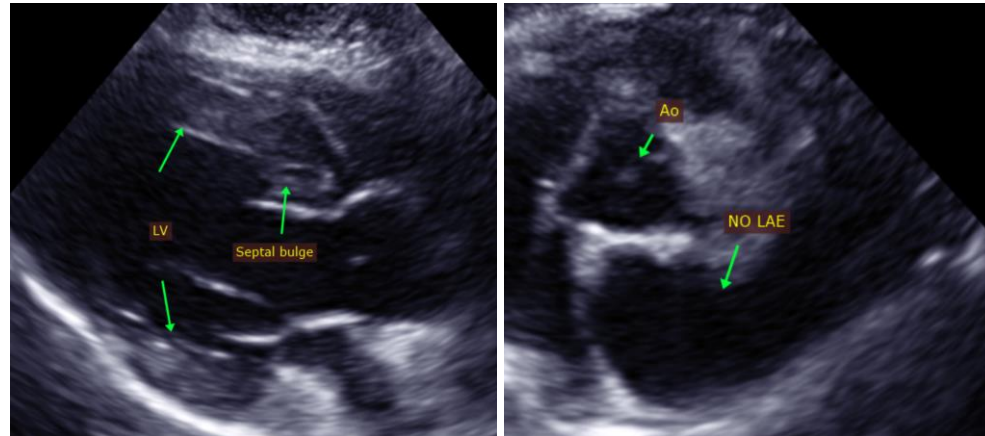
RECOMMENDATIONS

- Given these findings, no medications are indicated.
- Monitor BP and T4 every 6 months.
- Anesthetic risk is considered mild, however judicious IV fluid rates are advised to avoid fluid overload. Additionally, drugs that stimulate heart rate should be avoided unless clinically necessary (glycopyrrolate, atropine). A reasonable protocol includes opioid/benzodiazepine premedication, propofol induction, isoflurane maintenance.
- Risk for complication with steroid use typically follows LA dilation, which in this case is low. That being said, any cat can experience unexpected signs of intolerance and monitoring of RR/RE is advised particularly in the initiation phase.
- Monitor for any clinical evidence of cardiac compromise, including respiratory changes and/or signs of a blood clot event (paralysis, neurologic changes, etc.).

PLAN

- Recommend recheck echocardiogram in 6-12 months to screen for progression, sooner if any clinical signs arise in the interim.

IMAGES



The information and recommendations provided are based on the images presented by the referring veterinarian. No evaluation can be communicated regarding pathology that was not visible in the image/video clips provided.

Thank you for this referral. This report was generated using transcription software, and minor dictation errors may be present. If the clinical or image interpretation does not parallel your findings or if I can be of any further assistance, please contact me.

Maggie Machen Lamy, DVM
 Diplomate of the American College of Veterinary Internal Medicine (Cardiology)
 info@sonopath.com